

## Case Report

# Disseminated Coccidioidomycosis: A Case Report from the United Kingdom

Al-Daraji WI, Al-Mahmoud RMW and Ilyas M

Division of Pathology, School of Molecular Medical Sciences, University of Nottingham, NG7 2UH, UK

Received 12 March 2008; Accepted and available online 4 June 2008

**Abstract:** We reported the first case of disseminated coccidioidomycosis from the UK successfully treated with amphotericin B, where skin biopsy was the initial clue for the correct diagnosis.

**Key Words:** Coccidioidomycosis, dissemination, skin

### Introduction

The first case of coccidioidomycosis was reported in Argentina by Posadas and Wernike in 1892. Rixford discovered a case in California in 1894 and with Gilchrist, published an extensive study in 1886. It was regarded in the US as a rare chronic, wasting, fatal granulomatous disease until when Gifford and Dikson showed that it is an acquired mild form disease in almost all persons who are exposed to it in endemic area. According to Wilson *et al*, only about 0.1% becomes seriously ill [1]. The condition is caused by *Coccidioides immitis*. Kaden depicted areas in the US, Honduras, Venezuela, and the Gran Chaco region in South America and reviewed the literature since 1928 [2].

Coccidioidomycosis has been and continues to be subject of intensive studies in the western regions of the US, where the condition is endemic. Immunologic tests and the diagnosis of not only coccidioidomycosis but also of histoplasmosis, cryptococcosis, candidiasis, North American blastomycosis and actinomycosis were evaluated in the review by Salvin [3].

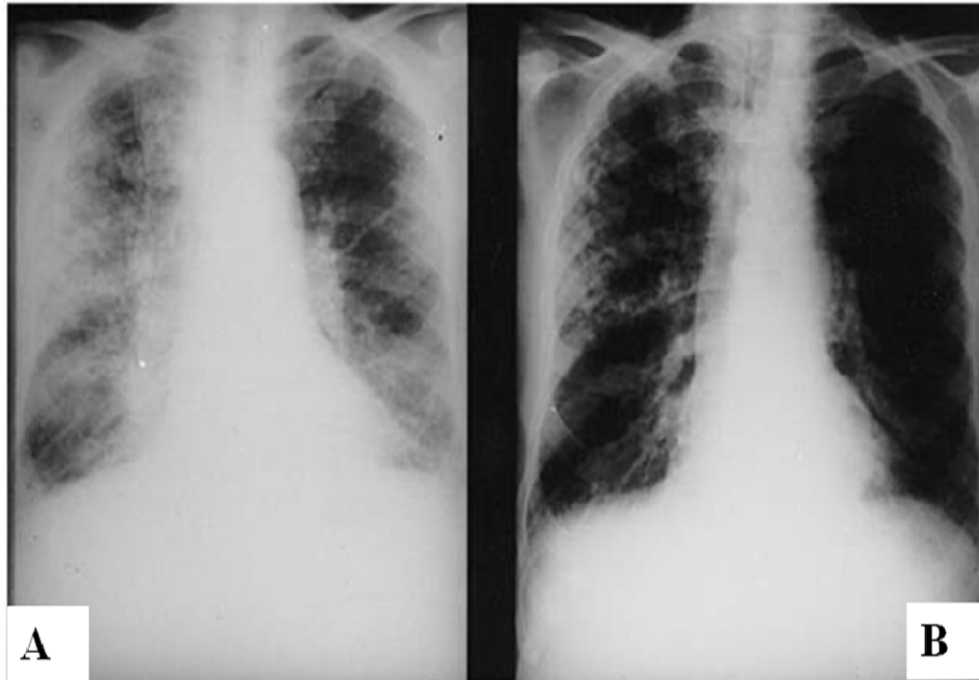
In endemic localities, the disease is spread by dust-borne spores of the fungus. The clinical manifestations, including cutaneous findings, were well described and illustrated by Wilson and Plunkett [1].

### Case Report

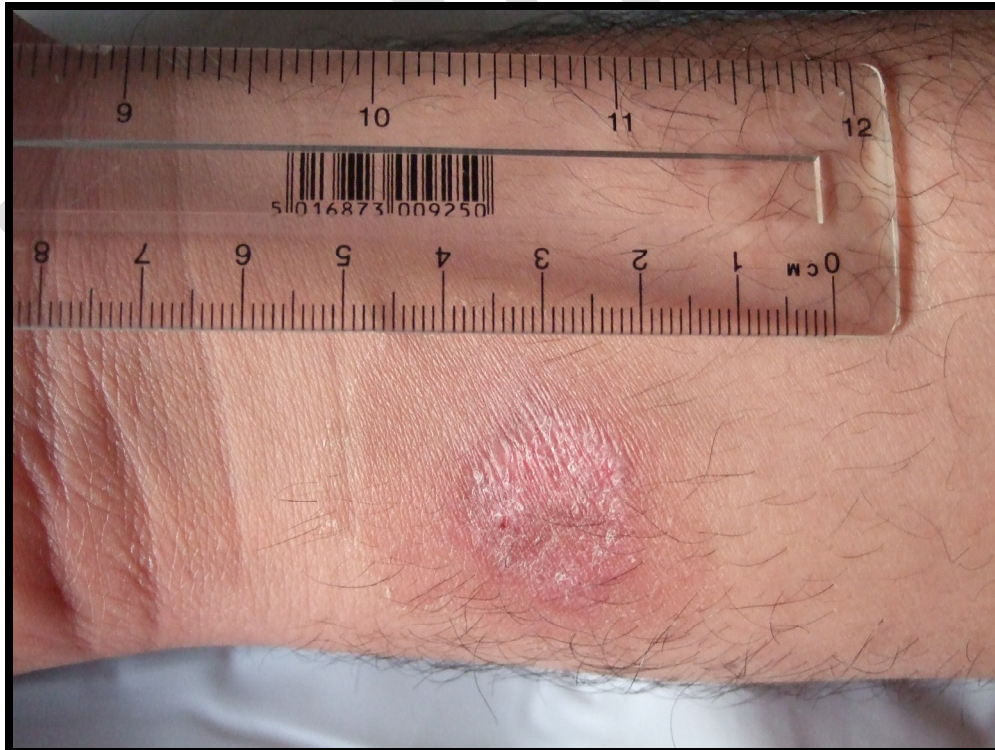A 43 year old female, a housewife with no contact with pets, presented with a history of fever, non-productive cough and chills. She also complained of chest pain, shortness of breath, headache and fatigue and skin lesions on her volar aspect of her right forearm. The skin lesion was present for 12 months. Physical examination was unremarkable except for increase in heart rate 120/min. Her respiratory rate was also increased (25/min). Her laboratory investigations were normal except for slight increase in eosinophils. Chest X Ray was obtained showing bilateral pulmonary infiltrate and enlarged hilar lymph nodes (**Figure 1A**), but no pleural effusion was present. She was HIV negative and her CD4 was within normal limits [4]. She had no travel history outside the UK for the last 3 years.

An annular skin lesion was noted on her right forearm measuring 5.7 x 4 x 3 cm with an annular rim (**Figure 2**). The lesion was painless. The surface of the lesion appeared to be crusted and according to the patient the lesion had persisted for one year.

The differential diagnoses at time of presentation were bacterial infection, Churg-Strauss syndrome, tuberculosis, sarcoidosis and *pneumocystis carinii* pneumonia. Examination of induced sputum obtained by bronchoscopy using Gram stain was normal.



**Figure 1** Chronic pulmonary coccidioidomycosis before (A) and after (B) treatment with Amphotericin B (0.7-1/mg/kg/day).



**Figure 2** An annular slightly erythematous rash with crust on the surface

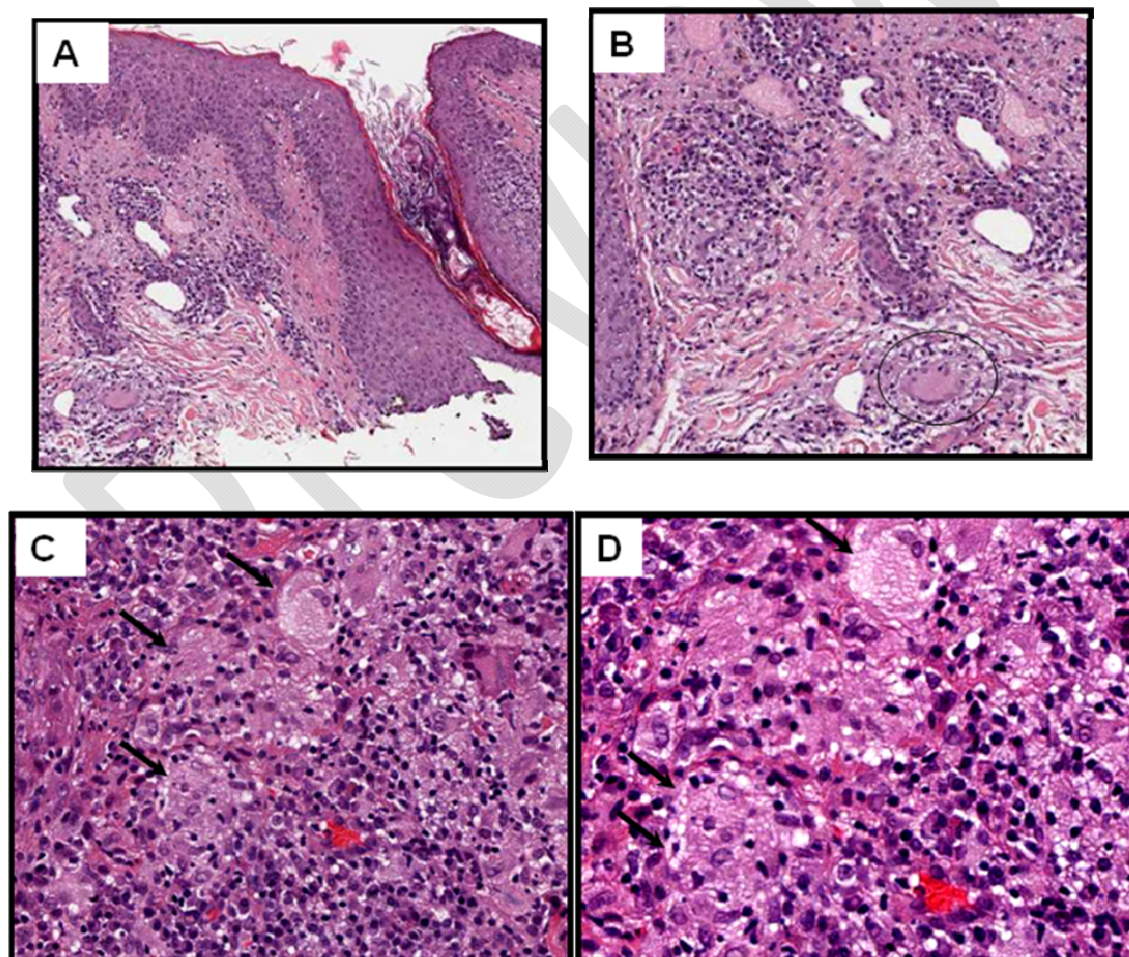
She was started on antibiotics for 3 weeks without improvement.

A skin biopsy was taken from her right forearm lesion (**Figure 2**) and showed spherules with endospores and a granulomatous nodule. These nodules contain multinucleated giant cells, mixed inflammatory infiltrate with plasma cells within the papillary dermis and upper reticular dermis. Multiple spherules that contains endospores were seen (**Figure 3**). There was no evidence of either erythema nodosum or erythema multiforme. Multiple serological tests showed that IgM as well as IgG (>1:32) were elevated. Culture confirmed the presence of *Coccidioides immitis*.

The diagnosis of coccidioidomycosis was made and the patient was initiated on amphotericin B (0.7-1 mg/kg/day) with dramatic improvement on her Chest X Ray after few weeks (**Figure 1B**). Therapy was continued until symptoms and signs of infection had resolved. In addition, treatment with itraconazole (200 mg twice a day) was continued for another 6 months. The latter agent is preferred because of less toxicity [5].

#### Discussion

*Coccidioides immitis* is a dimorphic fungus existing as mycelia in soil that can form small arthroconidia (5- $\mu$ m barrel-shaped structures). Arthroconidia can become air-borne and then



**Figure 3** A skin biopsy was taken from her right forearm and showed spherules with endospores and a granulomatous nodule. These nodules contain multinucleated giant cells, mixed inflammatory infiltrate with plasma cells within the papillary dermis and upper reticular dermis. Multiple spherules containing endospores were seen (circle and arrow heads).

inhaled by humans where they become lodged in the terminal bronchioles. In the warm, moist environment of the lungs the arthroconidia transform into spherules. As spherules mature, their outer walls become thinner and they release endospores that are ingested by macrophages. As in tuberculosis macrophages transport these infectious particles to the hilar lymph nodes, the lymphatic system, and the bloodstream, resulting in dissemination. Cell mediated immunity is critical for the control of infection [4, 6-10].

Transmission from human to human has not been documented, nor the transmission from one mammal to another. Dogs, horses and other animals also become infected after inhaling arthroconidia. A single case, where a veterinarian who may have acquired infection while performing necropsy on a horse has been reported [11].

Examination of induced sputum should use Silver stain, as Gram stain cannot detect the fungus to avoid delay in diagnosis and treatment.

Pulmonary lesions may be miliary and form 1 to 3 mm up to several centimeters across. The thin walled cavity noted sometimes in Chest X Ray has a wall several millimeters thick.

Microscopically, *Coccidioides immitis* can be identified in synovial, pleural, pericardial or peritoneal fluids, but the diagnosis is more successful when tissue specimens are examined. Active lesions contain numerous organisms, and diagnostic endosporeulating spherules are easily seen in hematoxylin-eosin stained tissue section (**Figures 3A-C**). There is usually a predominantly suppurative reaction to the recently released endospores and granulomatous reaction to maturing spherules (**Figure 3D**).

*Coccidioides immitis* has one remarkable distinction from other fungal infections as ketoconazole, itraconazole, amphotericin B and many other anti-fungals are effective in eliminating the organisms. However, there is no effective vaccine or other preventive

measure available yet.

In summary, we report the first case of disseminated coccidioidomycosis in the UK who was successfully treated with amphotericin B and skin biopsy was the clue for the correct diagnosis.

Please address all correspondences to Al-Daraji WI, MD, University of Nottingham, School of Molecular Medical Sciences, Division of pathology, Nottingham NG7 2UH, UK. Email: [waldaraji@aol.com](mailto:waldaraji@aol.com)

## References

- [1] Lewis GM, Hopper ME, Wilson JW and Pumkett OA. An introduction to Medical mycology, 4th ed: The Year Book Publishers, Chicago, 1958.
- [2] Kaden R. "Die Coccidioidomycose (Granuloma coccidioides, Granuloma coccidioidale, Talfieber, Wuternhumaistimus, San Joaquin-Fieber, Posada-Wernicke-Krantheit)." Vol 4. Berlin: Springer, 1963.
- [3] Salvin SB. Current concepts in diagnostic serology and skin hypersensitivity in the mycoses. *Am J Med* 1959; 27:97-114.
- [4] Cockerell CJ. Cutaneous fungal infections in HIV/AIDS. *J Int Assoc Physicians AIDS Care* 1995;1:19-23.
- [5] Yoshikawa TT. Drugs for fungal infections. *Am Fam Physician* 1980;22:145-150.
- [6] Morino E, Naka G, Izumi S, Yoshizawa A, Kawana A, Toyota E, Kobayashi N and Kudo K. [Case of cavitary coccidioidomycosis with fungus balls in the apices of both lungs]. *Nihon Kokyuki Gakkai Zasshi* 2006;44:711-715.
- [7] Ivanov AI. [Coccidioidomycosis (a review of the literature)]. *Voen Med Zh* 1968;11:16-22.
- [8] Rivitti EA and Aoki V. Deep fungal infections in tropical countries. *Clin Dermatol* 1999;17: 171-190.
- [9] Toriello C, Reyes-Montes MR and Taylor ML. [Production of fungal antigens from local strains for the immunodiagnosis of mycoses in Mexico]. *Rev Invest Clin* 1997;49:501-505.
- [10] Levine HB, Restrepon A, Eyck DR and Stevens DA. Spherulin and coccidioidin: cross-reactions in dermal sensitivity to histoplasmin and paracoccidioidin. *Am J Epidemiol* 1975; 101:512-516.
- [11] Kohn GJ, Linne SR, Smith CM and Hoeprich PD. Acquisition of coccidioidomycosis at necropsy by inhalation of coccidioidal endospores. *Diagn Microbiol Infect Dis* 1992; 15:527-530.