

Original Article

Over-expressed CD147 may be a reminder of tumor progression in cervical lesions: an immunohistochemical investigation with 494 cases

Wen-Ting Huang^{1*}, Li Gao^{1*}, Rong-Quan He², Jie Ma², Kang-Lai Wei¹, Gang Chen¹

Departments of ¹Pathology, ²Medical Oncology, First Affiliated Hospital of Guangxi Medical University, Nanning, Guangxi Zhuang Autonomous Region, P. R. China. *Equal contributors.

Received December 23, 2016; Accepted January 15, 2017; Epub March 1, 2017; Published March 15, 2017

Abstract: Background: CD147 plays a pivotal in the process of many malignancies. It remains unclear whether CD147 expression has clinical significance with cervical lesions. The current research was aimed to assess the expression of CD147 and investigate its relevance with the tumorigenesis and clinicopathological progression of cervical cancer. Materials and methods: Immunohistochemistry was conducted to evaluate the expression of CD147 within a total of 494 cases of cervical lesions, which were composed of chronic cervicitis (n=54), condyloma acuminatum (CA, n=42), carcinoma in situ (CIS, n=38), adenocarcinoma (n=63), squamous cell carcinoma (SCC, n=263) and adenosquamous carcinoma (n=34). SPSS 22.0 was used to analyze the relationship of CD147 expression and clinicopathological features of cervical lesions. CBioPortal was used to assess the OncoPrint of CD147 based on the data from The Cancer Genome Atlas (TCGA), and the prognostic value of CD147 in cervical cancer was shown by OncoInC. Results: CD147 expression showed a positive rate of 22.2%, 31.0%, 42.1%, 55.6%, 66.5% and 64.7% from chronic cervicitis, CA, CIS to adenocarcinoma, SCC and adenosquamous carcinoma, respectively. CD147 expression level was statistically higher in cancer than non-cancerous tissues (P<0.001). Results from Spearman correlation test confirmed that CD147 had positive correlation with age, lymph node metastasis, FIGO stage, TNM stage, as well as pathological grade (all P<0.05) in adenocarcinoma. As for SCC, CD147 was positively related to lymph node metastasis, FIGO stage, TNM stage and pathological grade (all P<0.001). In adenosquamous carcinoma, a positive correlation was observed between CD147 and lymph node metastasis, FIGO stage and TNM stage (all P<0.05). Furthermore, Gene alteration of 79 among 307 cases (26%) was shown by CBioPortal based on RNA-seq data. Conclusions: CD147 may have a significant effect on the tumorigenesis and progression of cervical cancer, and it is anticipated to be a potential diagnostic and therapeutic biomarker.

Keywords: CD147, cervical lesion, immunohistochemistry, progression

Introduction

Cervical cancer ranks the fourth in lethal women cancers worldwide [1]. In 2012, an estimated 527,600 cases of cervical cancer was newly reported and the death number of it was over 200,000 [2, 3]. Early cervical cancer can be effectively cured by surgical removal of tumor and radiotherapy, while the prognosis of locally advanced cancer is poor, although concurrent chemotherapy is adopted currently to treat this cancer [4-10]. Thus, a novel biomarker is urgently needed to improve the diagnosis and therapy of cervical cancer.

CD147, a trans-membrane protein, also called Basigin [11] or extracellular matrix metalloproteinases inducer (EMMPRIN) [12, 13], is a

member of the Ig superfamily [14] widely existing in normal human tissues and participate in various physiological and pathological process such as tissue repair, pregnancy, and embryo development [15, 16]. Previous studies have reported that CD147 is over-expressed in a broad type of cancers, and CD147 contributes to the invasive and metastatic capability, as well as angiogenesis through inducing molecules, such as matrix metalloproteinases (MMPs), vascular endothelial growth factor (VEGF) and hyaluronan, by tumor cells [14, 17-19]. Nevertheless, only several studies to date have reported on the correlation between CD147 expression and the clinicopathological features of cervical lesions. Yu et al [20] performed immunohistochemical staining to exam-

ine the score of CD147 of tumor cells with 65 samples of invasive squamous cell carcinoma of the uterine cervix. And Xu et al [21] carried out similar investigation with 110 cases with cervical cancer. Due to the small sample size and inconsistent findings from different groups, herein, we attempted to evaluate the expression of CD147 in cervical lesions with a larger cohort (n=494) and elucidate the relevance of CD147 expression and the development of cervical lesions.

Materials and methods

Materials

A total of 494 operated cases collected from the First Affiliated Hospital of Guangxi Medical University were retrospectively analyzed during a period of January, 2011 to December, 2014. We set exclusion criteria as follows: (1) Tissues with a diameter <0.5 cm was excluded to preserve the clinical diagnostic evidence; (2) Tissues were excluded if a separation from the slide happened in immunohistochemistry. As a result, we enrolled 494 cases of cervical lesions including cervical cancers (n=398) and non-cervical cancers (n=96) in our study.

All cervical cancer patients were clinically staged on the basis of International Federation of Gynecology and Obstetrics (FIGO) criteria 2009 (Stage I-II, n=264; Stage III-IV, n=96). Pathological grading was available for only 328 cases and was assessed in terms of the criteria of World Health Organization (WHO) (Grade I, n=28; Grade II, n=157; Grade III, n=141). TNM stage of cancer was graded based on American Joint Committee on Cancer (AJCC) Cervix Uteri Cancer Staging 7th edition (TNM stage I-II, n=302; TNM stage III-IV, n=96). Among the 360 cases of cervical cancer excluding CIS, lymph node metastasis was found in 96 patients. Radiotherapy or chemotherapy was not performed in all the selected patients. An agreement was reached in all patients and board-approved written documents of institutional review were signed from all patients. Approval of the research was given by the Ethics Committee of the First Affiliated Hospital of Guangxi Medical University.

Immunohistochemical staining

The pathologically diagnosed cervical lesion tissues were fixed in 10% neutral-buffered formalin. According to the size of the tissue, the fixation time ranged from 24-48 h. Sub-

sequently, tissues embedded in paraffin were sliced into 4 µm thick sections to be fixed on the slides. HE staining was conducted on the sections. Slides underwent a series of procedures: high pressure hot fix, immunohistochemical PV and DAB chromogenic, hematoxylin relying, hydrochloric acid-alcohol differentiation, anhydrous ethanol dehydration, neutral gum sealing peace. Immunostaining for CD147 was performed using and immunohistochemical kit purchased from Beijing Jinqiao Biological Co. LTD. All steps were strictly implemented under the manufacturer's instructions. PBS of 0.01 mol/L (pH7.4) was set as a negative control. A light microscope was used to observe the immunostaining and tissues with claybank granules were considered to show a positive expression of CD147.

Immunohistochemical scoring

An evaluation of the immunostaining was conducted by two authors (Kang-Lai Wei and Gang Chen) independently. CD147 expression was assessed semi-quantitatively based on the criteria as follows: no staining was classified as 0 point; weak staining showing focal or fine granular was classified as 1 point; moderate staining presenting as linear or cluster pattern was classified as 2 points and strong staining with diffuse, intense pattern was classified as 3 points. Staining intensity was scored by the amounts of positive cells: 0 point for no staining; 1 point for <30%; 2 points for 30%-70% and 3 points for >70%. The samples were divided into negative or positive group depending on the sum of the scores above as following: 0-2 points as negative and 3-9 points as positive.

Clinical role of CD147 in cervical cancer based on TCGA data

CBioPortal (www.cbioportal.org) was used to assess the OncoPrint of CD147 based on the data from The Cancer Genome Atlas (TCGA). The figure of OncoPrints was presented with the gene alterations on the basis of Cervical Squamous Cell Carcinoma (TCGA, provisional) with 307 cases. Moreover, the prognostic value of CD147 in cervical squamous cell carcinoma (TCGA, provisional) was shown by OncoInC with 264 cases with complete follow-up information.

Statistical analysis

The software SPSS 22.0 was used to study the statistical significance of the expression of

Over-expressed CD147 in cervical cancers

Table 1. Relationship of CD147 and expression with other clinicopathological variables

	Total number	No. patients, stratified by CD147		Z	P-value
		Negative (221)	Positive (273)		
Cancer VS non-cancer				-6.409	P<0.001*
Cancer tissues	398	150 (37.7%)	248 (62.3%)		
Non-cancer tissues	96	71 (74.0%)	25 (26.0%)		
Histological type				51.199 ^a	P<0.001*
Chronic cervicitis	54	42 (77.8%)	12 (22.2%)		
CA	42	29 (69.0%)	13 (31.0%)		
Carcinoma in situ	38	22 (57.9%)	16 (42.1%)		
Adenocarcinoma	63	28 (44.4%)	35 (55.6%)		
SCC	263	88 (33.5%)	175 (66.5%)		
Adenosquamous carcinoma	34	12 (35.3%)	22 (64.7%)		
Age				-1.330	0.183
≤44	263	125 (47.5%)	138 (52.5%)		
>44	231	96 (41.6%)	135 (58.4%)		
Pathological grade				25.833 ^a	P<0.001*
I	28	16 (57.1%)	12 (42.9%)		
II	157	71 (45.2%)	86 (54.8%)		
III	141	29 (20.6%)	112 (79.4%)		
TNM stage				-8.495	P<0.001*
I-II	302	149 (49.3%)	153 (50.7%)		
III-IV	96	1 (1.0%)	95 (99.0%)		
Lymph node metastasis				-8.238	P<0.001*
Negative	264	127 (48.1%)	137 (51.9%)		
Positive	96	1 (1.0%)	95 (99.0%)		
FIGO stage				-8.238	P<0.001*
I-II	264	127 (48.1%)	137 (51.9%)		
III-IV	96	1 (1.0%)	95 (99.0%)		

Abbreviations: CA, Condyloma acuminates; SCC, Squamous cell carcinoma; TNM, The TNM (Tumor, lymph nodes, metastasis) Classification of Malignant Tumors; FIGO, International Federation of Gynecology and Obstetrics. Notes: P-value (*P<0.05) was from non-parametric test (Mann-Whitney U test or ^aKruskal-Wallis H test was performed).

CD47. Mann-Whitney U test and Kruskal-Wallis H test was used to examine the difference of CD147 expression with clinicopathological factors between groups. The relevance between CD147 expression and clinicopathological features was calculated by Spearman's correlation test. Kaplan-Meier method was applied to assess the prognostic value of CD147 in cervical cancer based on TCGA data. Statistical significance was accepted when P-value <0.05.

Results

CD147 expression in cervical lesions

Four hundred and ninety-four cervical specimens in total were involved in our study (Table 1). As illustrated in Figure 1, different expres-

sion mode of CD147 in cervical tissues was obtained by immunohistochemical analysis. Results from the immunostaining indicated that the positive rate of CD147 expression was 22.2% in chronic cervicitis, 31.0% in CA, 42.1% in carcinoma in situ, 55.6% in adenocarcinoma, 66.5% in SCC and 64.7% in adenosquamous carcinoma. CD147 presented a higher expression level in cervical cancer (carcinoma in situ, adenocarcinoma, SCC and adenosquamous carcinoma) (62.3%) compared with non-cancer cervical tissues (chronic cervicitis and CA) (26.0%) (P<0.001). We also found that the expression of CD147 varied between groups with different pathological grade. The positive rate of CD147 expression was 42.9%, 54.8%, 79.4% in grade I, II and III, respectively (P<0.001). Similarly, CD147 was more highly over-expre-

Over-expressed CD147 in cervical cancers

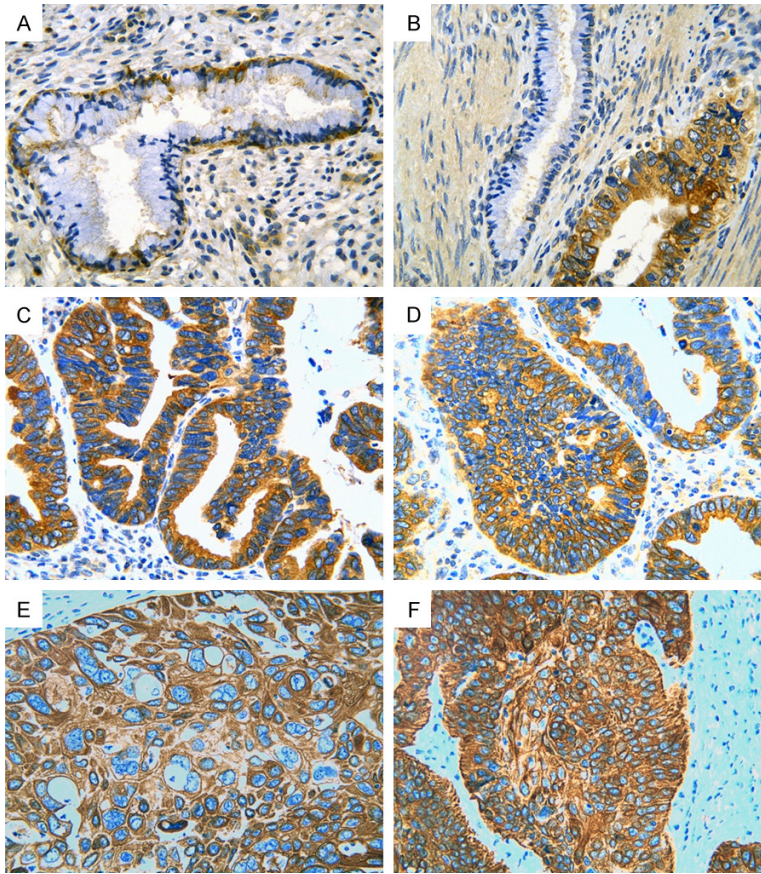


Figure 1. Immunohistochemical staining for CD147 in cervical lesions. Weakly CD147 expression was observed in epithelial cytoplasm of a cervical polyp (A). In cervical adenocarcinoma, strong CD147 positive signaling was observed in atypical hyperplasia glands. On the contrary, no staining was found in normal gland (B and C). CD147 positivity was found in a case of cervical adenosquamous carcinoma (D) and squamous cell carcinoma (E and F). Immunohistochemistry, 400 \times .

Table 2. The correlation between CD147 expression and clinicopathological factors in cervical tissues

Variable	r	P
Cancer VS non-cancerous	-0.289	P<0.001*
Histological type	0.316	P<0.001*
Age	0.060	0.184
Pathological grade	0.276	P<0.001*
TNM stage	0.426	P<0.001*
Lymph node metastasis	0.435	P<0.001*
FIGO stage	0.435	P<0.001*

Abbreviations: TNM, The TNM (Tumor, lymph nodes, metastasis) Classification of Malignant Tumors; FIGO, International Federation of Gynecology and Obstetrics. Notes: *P<0.05.

ssed in advanced TNM stage (III-IV) (99.0%) than in early TNM stage (I-II) (50.7%) (P<0.001).

CD147 expression in cancer tissues with lymph node metastasis (99.0%) was higher in comparison with negative group (51.9%) (P<0.001). Additionally, the expression of CD147 was observed to be higher in advanced FIGO stage (III-IV) (99.0%) than in early FIGO stage (I-II) (51.9%, P<0.001). Thus, the results demonstrated that the expression of CD147 was indicative of the tumorigenesis and development of cancer.

Relationship between CD147 expression and clinicopathological features of cervical lesions

As shown in **Table 2**, the relationship between the expression of CD147 and clinicopathological features were assessed by Spearman's correlation test. The results revealed that CD147 correlated positively with histological type (r=0.316, P<0.001), pathological grade (r=0.276, P<0.001), TNM stage (r=0.426, P<0.001), lymph node metastasis (r=0.435, P<0.001) and FIGO stage (r=0.435, P<0.001), while there was no

significant relationship between CD147 expression and age (r=0.060, P=0.184).

Expression of CD147 associated to clinicopathological features in cervical cancers

As shown in **Table 3**, the correlation between CD147 expression and varied clinical factors in adenocarcinoma were investigated. CD147 expression was significantly higher in older patients (>44 years) (69.4%) than in younger patients (37.0%, P=0.011). CD147 expression was statistically different in groups with varied pathological grades (grade I, grade II and grade III). The positive rate of CD147 expression was 40.0%, 47.4% and 55.6% in grade I, II and III, respectively. CD147 was more over-expressed in advanced TNM stage (III-IV) (94.4%) than in early TNM stage (I-II) (40.0%, P<0.001). We also observed a higher CD147 expression

Over-expressed CD147 in cervical cancers

Table 3. Relationship of CD147 expression with other clinicopathological variables in adenocarcinoma

Characteristic	Total number	No. patients, stratified by CD147		Z	P-value
		Negative (28)	Positive (35)		
Age				-2.541	0.011*
≤44	27	17 (63.0%)	10 (37.0%)		
>44	36	11 (30.6%)	25 (69.4%)		
Pathological grade				7.766 ^a	0.021*
I	10	6 (60.0%)	4 (40.0%)		
II	38	20 (52.6%)	18 (47.4%)		
III	15	2 (13.3%)	13 (86.7%)		
TNM stage				-3.897	P<0.001*
I-II	45	27 (60.0%)	18 (40.0%)		
III-IV	18	1 (5.6%)	17 (94.4%)		
Lymph node metastasis				-3.897	P<0.001*
Negative	45	27 (60.0%)	18 (40.0%)		
Positive	18	1 (5.6%)	17 (94.4%)		
FIGO stage				-3.897	P<0.001*
I-II	45	27 (60.0%)	18 (40.0%)		
III-IV	18	1 (5.6%)	17 (94.4%)		

Abbreviations: TNM, The TNM (Tumor, lymph nodes, metastasis) Classification of Malignant Tumors; FIGO, International Federation of Gynecology and Obstetrics. Notes: P-value (*P<0.05) was from non-parametric test (Mann-Whitney U test or ^aKruskal-Wallis H test was performed).

in tumor tissues with lymph node metastasis (94.4%) than in negative group (40.0%) (P<0.001). CD147 showed a remarkably higher level of expression in advanced FIGO stage (III-IV) (94.4%) compared with early FIGO stage (I-II) (40.0%, P<0.001). The above results indicated that CD147 was positively related to age, pathological grade, TNM stage, lymph node metastasis and FIGO stage in adenocarcinoma.

The relationship of CD147 expression and clinical variables in SCC were displayed in **Table 4**. The expression of CD147 bared a statistical significance in different pathological groups (P<0.001). In advanced TNM stage (III-IV), CD147 expression was higher (100.0%) than in early TNM stage (I-II) (54.4%, P<0.001). CD147 expression was higher in patients with lymph node metastasis (100.0%) than in those patients without lymph node metastasis (54.4%, P<0.001). In advanced FIGO stage (III-IV), CD147 expression was also observed to be higher (100.0%) than in early FIGO stage (I-II) (54.4%, P<0.001). Positive relevancies were found between CD147 expression and pathological grade, TNM stage, lymph node metastasis and FIGO stage in SCC.

The relationships between CD147 expression and clinical parameters in adenosquamous carcinoma were shown in **Table 5**. The expression of CD147 was higher in advanced TNM stage (III-IV) (100.0%) than in early TNM stage (I-II) (53.8%, P<0.001). Groups with lymph node metastasis showed a higher level of CD147 expression (100.0%) than in groups without lymph node metastasis (53.8%, P<0.001). Similarly, CD147 expression was up-regulated in advanced FIGO stage (III-IV) (100.0%) compared with that in early FIGO stage (I-II) (53.8%, P<0.001). A positive correlation was found between CD147 expression and TNM stage, lymph node metastasis and FIGO stage in adenosquamous carcinoma.

Gene alterations of CD147 in cervical cancers based on TCGA data

Altogether, 79 among 307 cases were detected to gain different types of gene alterations, such as amplification, deep deletion, mRNA upregulation, mRNA downregulation, truncating mutation and missense mutation (putative passenger) as shown in **Figure 2**. We attempted to evaluate the clinical role of these gene alterations of CD147, however, no significant value

Over-expressed CD147 in cervical cancers

Table 4. Relationship of CD147 expression with other clinicopathological variables in SCC

Characteristic	Total number	No. patients, stratified by CD147		Z	P-value
		Negative (88)	Positive (175)		
Age				-0.738	0.461
≤44	138	49 (35.5%)	89 (64.5%)		
>44	125	39 (31.2%)	86 (68.8%)		
Pathological grade				16.795 ^a	P<0.001*
I	18	10 (55.6%)	8 (44.4%)		
II	119	51 (42.9%)	68 (57.1%)		
III	126	27 (21.4%)	99 (78.6%)		
TNM stage				-6.913	P<0.001*
I-II	193	88 (45.6%)	105 (54.4%)		
III-IV	70	0 (0.0%)	70 (100.0%)		
Lymph node metastasis				-6.913	P<0.001*
Negative	193	88 (45.6%)	105 (54.4%)		
Positive	70	0 (0.0%)	70 (100.0%)		
FIGO stage				-6.913	P<0.001*
I-II	193	88 (45.6%)	105 (54.4%)		
III-IV	70	0 (0.0%)	70 (100.0%)		

Abbreviations: TNM, The TNM (Tumor, lymph nodes, metastasis) Classification of Malignant Tumors; FIGO, International Federation of Gynecology and Obstetrics. Notes: P-value (*P<0.05) was from non-parametric test (Mann-Whitney U test or *Kruskal-Wallis H test was performed).

Table 5. Relationship of CD147 expression with other clinicopathological variables in adenosquamous carcinoma

Characteristic	Total number	No. patients, stratified by CD147		Z	P-value
		Negative (12)	Positive (22)		
Age				-0.503	0.615
≤44	19	6 (31.6%)	13 (68.4%)		
>44	15	6 (40.0%)	9 (60.0%)		
TNM stage				-2.353	0.019*
I-II	26	12 (46.2%)	14 (53.8%)		
III-IV	8	0 (0.0%)	8 (100.0%)		
Lymph node metastasis				-2.353	0.019*
Negative	26	12 (46.2%)	14 (53.8%)		
Positive	8	0 (0.0%)	8 (100.0%)		
FIGO stage				-2.353	0.019*
I-II	26	12 (46.2%)	14 (53.8%)		
III-IV	8	0 (0.0%)	8 (100.0%)		

Abbreviations: TNM, The TNM (Tumor, lymph nodes, metastasis) Classification of Malignant Tumors; FIGO, International Federation of Gynecology and Obstetrics. Notes: P-value (*P<0.05) was from non-parametric test (Mann-Whitney U test was performed).

was found in the progression or survival of cervical cancers (data not shown). Since CD147 expression was obviously higher in cervical cancer tissues than non-cancerous tissues as assessed by immunohistochemistry, we then examined the prognostic role of CD147 expression in cervical cancer with Oncolnc. Again, no

significant difference of survival time was noted between high and low CD147 groups (**Figure 3**).

Discussion

Cervical cancer is one of the most frequent malignancies threatening the lives of women

Over-expressed CD147 in cervical cancers

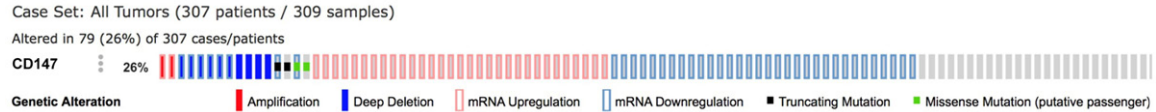


Figure 2. OncoPrint of CD147 from TCGA data shown by CBioPortal. Altogether, 26% gene alterations were noted from 307 patients.

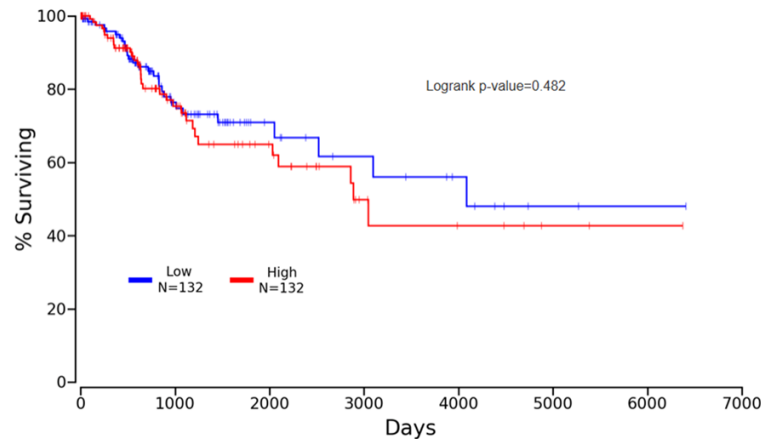


Figure 3. Prognostic role of CD147 in cervical cancer based on TCGA data from OncoPrint. No significant difference of surviving rate was noted between high and low CD147 groups.

[1, 22, 23], constituting a considerable disease burden in affected area. Despite great effort has been made to enhance the diagnostic approach and treatment of cervical cancer, the survival rate of patients with metastatic cervical cancer was less than one fifth of that in localized cancer [24-26]. Hence, it is imperative to develop a novel diagnostic and therapeutic target for the cervical cancer treatment. The genesis and progression of cervical cancer is still a complex process far from elucidation. Multiple molecules and genes may engage in cervical cancer [27-29].

CD147 is an extracellular matrix metalloproteinases inducer [12]. Involvement in cell recognition and induction of the production of extracellular MMPs comprise the main function of CD147 [16]. Secretion of MMP by tumor cells and neighboring stromal fibroblasts can facilitate tumor invasiveness and metastasis [30]. The expression of CD147 is significantly higher in various types of cancers than in normal human tissues [31]. These findings provide evidence that CD147 could be a promising target for the diagnosis and treatment of some cancer.

In this research, we endeavored to clarify the CD147 expression in cervical tissues and its clinical significance in cervical cancers through immunohistochemistry. As for the clinical role of CD147 in the carcinogenesis of cervical cancer, Yu et al [20] reported that CD147 expression was elevated remarkably in cervical cancer compared to the tissues of cervical epithelium of chronic cervicitis with 65 cases being involved. Consistently, CD147 expression protein content was also detected to be overexpressed in cervical carcinoma tissues

than normal cervical tissues with 110 cases, as documented by Xu et al [21]. The results from our current study demonstrated consistent significantly higher CD147 expression in cancer tissues in comparison with that in non-cancer tissues, which implied that CD147 may participate in the tumorigenesis of cervical cancer.

When concerning the function of CD147 in the process of the deterioration of cervical cancer, Yu et al [20] showed that CD147 expression was correlated with invasion, metastasis of squamous cell carcinoma of the uterine cervix, while Xu et al [21] indicated that strong expression of CD147 was closely associated with stages, lymph node metastasis, differentiation, and parametrium invasion of cervical carcinoma. Furthermore, overexpression of CD147 was markedly related to short progression-free survival and overall survival of cervical carcinoma. In the current study, the assessment of the relationship between CD147 expression and clinicopathological features in cervical lesions from Spearman's correlation test indicated that the expression of CD147 was concordantly positively related to lymph node metas-

tasis, histological type, FIGO stage, TNM stage and pathological grade, which suggests that CD147 plays an essential part in cervical cancer invasiveness and metastasis, in line with previous reports [20, 21]. More importantly, we further analyzed the relationship of CD147 expression with clinical variables in different subtypes of cervical cancers. Consistently, CD147 expression was closely interrelated to lymph node metastasis, FIGO stage, TNM stage and pathological grade in both adenocarcinoma and SCC. In adenosquamous carcinoma, significant relationship was found between CD147 expression and lymph node metastasis, FIGO stage and TNM stage. The age of patients was only statistically correlated with CD147 expression in adenocarcinoma, which needs to be verified by experiments with larger size of sample. The results from the current study, together with previous analyses reveal that CD147 may exert an influence on the deterioration of cervical cancer.

However, the molecular mechanism which exerts the clinical function of CD147 in cervical diseases remains still uncertain. Recent studies proved that CD147 may promote the carcinogenesis and progression in different cancers via various molecular mechanisms. Fang et al reported that CD147 may promote the proliferation of prostate by regulating Akt/GSK-3 β / β -catenin/AR signaling network [32]. In HCC, CD147 may facilitate the metastatic capacity of cancer cells by increasing the expression of β -h3 as well as modulating downstream metastasis-related genes including FAK, Girdin, Src and signal transducer and activator of transcription 3 (STAT3) [33-35]. Luo et al reported that the invasion and metastasis of melanoma may be attributed to CD147 ubiquitinated by TRAF6 and the subsequent induction of MM9 [12]. DOCK3 is one member of the DOCK GEF family mainly expressed in neuronal tissues [36], participating in cell adhesion and axonal degeneration. Additionally, DOCK 3 is also expressed in non-neuronal tissues with a function of regulating cell movement via GEF activity [37, 38]. Study conducted by Cui et al indicated that an inhibition of Annexin A2 phosphorylation on tyrosine 23 by Src could be triggered by binding with CD147. Annexin A2 phosphorylation induced the production of DOCK3 and WAVE2 expression was down-regulated by DOCK3 through regulating beta-catenin signaling. In this way, CD147 promoted cell movement via p-Annexin A2-DOCK3- β -catenin-WAVE2 signal-

ing axis [39]. The results of the above-mentioned studies may provide an insight into the mechanism underlying the tumorigenesis and progression of cervical cancer. But limited studies to date have focused on the molecular mechanism of CD147 in cervical cancer. Co-expression of CD147 with other molecules such as MMP-2, MMP-9, MCT1, MCT4 and GLUT-1 was considered as clinically significant in cervical cancer [20, 40-42]. With *in vitro* experiments [21], ADAM17 RNA interference could decrease CD147 protein in SiHa and HeLa cells. These findings were in accordance with our study that CD147 expression was indicative of the genesis and progression of cervical cancer. Furthermore, we found from the TCGA data, several types of gene alterations of CD147 existed in cervical cancer. However, the exact underlying molecular mechanism of CD147 in the tumorigenesis and development of cervical cancer remains to be systematically explored with further *in vitro* and *in vivo* experiments.

In conclusion, CD147 is of clinical significance in the oncogenesis and development of cervical cancer. We anticipated that the result of the study may support CD147 as a novel biomarker to develop the diagnostic and therapeutic strategies of cervical cancer.

Acknowledgements

This study was supported by grants from Natural Science Foundation of Guangxi, China (#2015GXNSFAA139187), Innovation Project of Guangxi Graduate Education (YCSZ2015106) and Guangxi Provincial Health Bureau Scientific Research Project (#Z2014057).

Disclosure of conflict of interest

None.

Address correspondence to: Drs. Kang-Lai Wei and Gang Chen, Department of Pathology, First Affiliated Hospital of Guangxi Medical University, 6 Shuangyong Road, Nanning 530021, Guangxi Zhuang Autonomous Region, P. R. China. Fax: +86 771 5358943; E-mail: yxwwkl@163.com (KLW); chen_gang_triones@163.com (GC)

References

- [1] Lee SJ, Yang A, Wu TC and Hung CF. Immunotherapy for human papillomavirus-associated disease and cervical cancer: review of clinical

Over-expressed CD147 in cervical cancers

- cal and translational research. *J Gynecol Oncol* 2016; 27: e51.
- [2] Shazly SA, Murad MH, Dowdy SC, Gostout BS and Famuyide AO. Robotic radical hysterectomy in early stage cervical cancer: a systematic review and meta-analysis. *Gynecol Oncol* 2015; 138: 457-471.
- [3] Zong S, Wang X, Yang Y, Wu W, Li H, Ma Y, Lin W, Sun T, Huang Y, Xie Z, Yue Y, Liu S and Jing X. The use of cisplatin-loaded mucoadhesive nanofibers for local chemotherapy of cervical cancers in mice. *Eur J Pharm Biopharm* 2015; 93: 127-135.
- [4] Cibula D, Abu-Rustum NR, Benedetti-Panici P, Kohler C, Raspagliesi F, Querleu D and Morrow CP. New classification system of radical hysterectomy: emphasis on a three-dimensional anatomic template for parametrial resection. *Gynecol Oncol* 2011; 122: 264-268.
- [5] Rose PG. Concurrent chemoradiation for locally advanced carcinoma of the cervix: where are we in 2006? *Ann Oncol* 2006; 17 Suppl 10: x224-229.
- [6] Diaz-Padilla I, Monk BJ, Mackay HJ and Oaknin A. Treatment of metastatic cervical cancer: future directions involving targeted agents. *Crit Rev Oncol Hematol* 2013; 85: 303-314.
- [7] Hsieh CJ, Hong MK, Chen PC, Wang JH and Chu TY. Antiestrogen use reduces risk of cervical neoplasia in breast cancer patients: a population-based study. *Oncotarget* 2016; [Epub ahead of print].
- [8] Ruan J, Mei L, Zhu Q, Shi G and Wang H. Mixed lineage kinase domain-like protein is a prognostic biomarker for cervical squamous cell cancer. *Int J Clin Exp Pathol* 2015; 8: 15035-15038.
- [9] Jung SH, Choi YJ, Kim MS, Baek IP, Lee SH, Lee AW, Hur SY, Kim TM, Lee SH and Chung YJ. Progression of naive intraepithelial neoplasia genome to aggressive squamous cell carcinoma genome of uterine cervix. *Oncotarget* 2015; 6: 4385-4393.
- [10] Xiang L, Li J, Jiang W, Shen X, Yang W, Wu X and Yang H. Comprehensive analysis of targetable oncogenic mutations in chinese cervical cancers. *Oncotarget* 2015; 6: 4968-4975.
- [11] Miyauchi T, Kanekura T, Yamaoka A, Ozawa M, Miyazawa S and Muramatsu T. Basigin, a new, broadly distributed member of the immunoglobulin superfamily, has strong homology with both the immunoglobulin V domain and the beta-chain of major histocompatibility complex class II antigen. *J Biochem* 1990; 107: 316-323.
- [12] Luo Z, Zhang X, Zeng W, Su J, Yang K, Lu L, Lim CB, Tang W, Wu L, Zhao S, Jia X, Peng C and Chen X. TRAF6 regulates melanoma invasion and metastasis through ubiquitination of Basigin. *Oncotarget* 2016; 7: 7179-7192.
- [13] Biswas C, Zhang Y, DeCastro R, Guo H, Nakamura T, Kataoka H and Nabeshima K. The human tumor cell-derived collagenase stimulatory factor (renamed EMMPRIN) is a member of the immunoglobulin superfamily. *Cancer Res* 1995; 55: 434-439.
- [14] Muramatsu T. Basigin (CD147), a multifunctional transmembrane glycoprotein with various binding partners. *J Biochem* 2016; 159: 481-490.
- [15] Lee CL, Lam MP, Lam KK, Leung CO, Pang RT, Chu IK, Wan TH, Chai J, Yeung WS and Chiu PC. Identification of CD147 (basigin) as a mediator of trophoblast functions. *Hum Reprod* 2013; 28: 2920-2929.
- [16] Yang XQ, Yang J, Wang R, Zhang S, Tan QW, Lv Q, Meng WT, Mo XM and Li HJ. Effect of specific silencing of EMMPRIN on the growth and cell cycle distribution of MCF-7 breast cancer cells. *Genet Mol Res* 2015; 14: 15730-15738.
- [17] Grass GD, Dai L, Qin Z, Parsons C and Toole BP. CD147: regulator of hyaluronan signaling in invasiveness and chemoresistance. *Adv Cancer Res* 2014; 123: 351-373.
- [18] Tang Y, Nakada MT, Kesavan P, McCabe F, Millar H, Rafferty P, Bugelski P and Yan L. Extracellular matrix metalloproteinase inducer stimulates tumor angiogenesis by elevating vascular endothelial cell growth factor and matrix metalloproteinases. *Cancer Res* 2005; 65: 3193-3199.
- [19] Garg K, Leitao MM Jr, Wynveen CA, Sica GL, Shia J, Shi W and Soslow RA. p53 overexpression in morphologically ambiguous endometrial carcinomas correlates with adverse clinical outcomes. *Mod Pathol* 2010; 23: 80-92.
- [20] Yu W, Liu J, Xiong X, Ai Y and Wang H. Expression of MMP9 and CD147 in invasive squamous cell carcinoma of the uterine cervix and their implication. *Pathol Res Pract* 2009; 205: 709-715.
- [21] Xu Q, Ying M, Chen G, Lin A, Xie Y, Ohara N and Zhou D. ADAM17 is associated with EMMPRIN and predicts poor prognosis in patients with uterine cervical carcinoma. *Tumour Biol* 2014; 35: 7575-7586.
- [22] Li L, Jiao GL, Qin S and Xiao Q. Relationship between hWAPL polymorphisms and cervical cancer susceptibility. *Int J Clin Exp Pathol* 2015; 8: 13777-13782.
- [23] Yu H, Zhang L, Du X and Sheng X. Postoperative adjuvant chemotherapy combined with intracavitary brachytherapy in early-stage cervical cancer patients with intermediate risk factors. *Onco Targets Ther* 2016; 9: 7331-7335.
- [24] Li H, Wu X and Cheng X. Advances in diagnosis and treatment of metastatic cervical cancer. *J Gynecol Oncol* 2016; 27: e43.
- [25] Chen X, Liu L and Zhu W. Up-regulation of long non-coding RNA CCAT2 correlates with tumor

Over-expressed CD147 in cervical cancers

- metastasis and poor prognosis in cervical squamous cell cancer patients. *Int J Clin Exp Pathol* 2015; 8: 13261-13266.
- [26] Chai Y, Wang J, Wang T, Shi F, Wang J, Su J, Yang Y, Zhou X, Ma H, He B and Liu Z. Cost-effectiveness of radical hysterectomy with adjuvant radiotherapy versus radical radiotherapy for FIGO stage IIB cervical cancer. *Onco Targets Ther* 2016; 9: 349-354.
- [27] Deng X, Zhang Y, Li D, Zhang X, Guo H, Wang F and Sheng X. Abdominal radical trachelectomy guided by sentinel lymph node biopsy for stage IB1 cervical cancer with tumors >2 cm. *Oncotarget* 2017; 8: 3422-3429.
- [28] Zeng X, Zhang Y, Yue T, Zhang T, Wang J, Xue Y and An R. Association between XRCC1 polymorphisms and the risk of cervical cancer: a meta-analysis based on 4895 subjects. *Oncotarget* 2017; 8: 2249-2260.
- [29] Hu YF, Lei X, Zhang HY, Ma JW, Yang WW, Chen ML, Cui J and Zhao H. Expressions and clinical significance of autophagy-related markers Beclin1, LC3, and EGFR in human cervical squamous cell carcinoma. *Onco Targets Ther* 2015; 8: 2243-2249.
- [30] Fisel P, Stuhler V, Bedke J, Winter S, Rausch S, Hennenlotter J, Nies AT, Stenzl A, Scharpf M, Fend F, Kruck S, Schwab M and Schaeffeler E. MCT4 surpasses the prognostic relevance of the ancillary protein CD147 in clear cell renal cell carcinoma. *Oncotarget* 2015; 6: 30615-30627.
- [31] Tang J, Guo YS, Yu XL, Huang W, Zheng M, Zhou YH, Nan G, Wang JC, Yang HJ, Yu JM, Jiang JL and Chen ZN. CD147 reinforces [Ca²⁺]_i oscillations and promotes oncogenic progression in hepatocellular carcinoma. *Oncotarget* 2015; 6: 34831-34845.
- [32] Fang F, Qin Y, Hao F, Li Q, Zhang W, Zhao C, Chen S, Zhao L, Wang L and Cai J. CD147 modulates androgen receptor activity through the Akt/Gsk-3beta/beta-catenin/AR pathway in prostate cancer cells. *Oncol Lett* 2016; 12: 1124-1128.
- [33] Tang J, Zhou HW, Jiang JL, Yang XM, Li Y, Zhang HX, Chen ZN and Guo WP. Beta1g-h3 is involved in the HAb18G/CD147-mediated metastasis process in human hepatoma cells. *Exp Biol Med (Maywood)* 2007; 232: 344-352.
- [34] Wang Y, Yuan L, Yang XM, Wei D, Wang B, Sun XX, Feng F, Nan G, Wang Y, Chen ZN and Bian H. A chimeric antibody targeting CD147 inhibits hepatocellular carcinoma cell motility via FAK-PI3K-Akt-Girdin signaling pathway. *Clin Exp Metastasis* 2015; 32: 39-53.
- [35] Wang SJ, Cui HY, Liu YM, Zhao P, Zhang Y, Fu ZG, Chen ZN and Jiang JL. CD147 promotes Src-dependent activation of Rac1 signaling through STAT3/DOCK8 during the motility of hepatocellular carcinoma cells. *Oncotarget* 2015; 6: 243-257.
- [36] Namekata K, Kimura A, Kawamura K, Guo X, Harada C, Tanaka K and Harada T. Dock3 attenuates neural cell death due to NMDA neurotoxicity and oxidative stress in a mouse model of normal tension glaucoma. *Cell Death Differ* 2013; 20: 1250-1256.
- [37] Chen Q, Peto CA, Shelton GD, Mizisin A, Sawchenko PE and Schubert D. Loss of modifier of cell adhesion reveals a pathway leading to axonal degeneration. *J Neurosci* 2009; 29: 118-130.
- [38] Tachi N, Hashimoto Y and Matsuoka M. MOCA is an integrator of the neuronal death signals that are activated by familial Alzheimer's disease-related mutants of amyloid beta precursor protein and presenilins. *Biochem J* 2012; 442: 413-422.
- [39] Cui HY, Wang SJ, Miao JY, Fu ZG, Feng F, Wu J, Yang XM, Chen ZN and Jiang JL. CD147 regulates cancer migration via direct interaction with Annexin A2 and DOCK3-beta-catenin-WAVE2 signaling. *Oncotarget* 2016; 7: 5613-5629.
- [40] Huang XQ, Chen X, Xie XX, Zhou Q, Li K, Li S, Shen LF and Su J. Co-expression of CD147 and GLUT-1 indicates radiation resistance and poor prognosis in cervical squamous cell carcinoma. *Int J Clin Exp Pathol* 2014; 7: 1651-1666.
- [41] Pinheiro C, Longatto-Filho A, Pereira SM, Etlinger D, Moreira MA, Jube LF, Queiroz GS, Schmitt F and Baltazar F. Monocarboxylate transporters 1 and 4 are associated with CD147 in cervical carcinoma. *Dis Markers* 2009; 26: 97-103.
- [42] Sier CF, Zuidwijk K, Zijlmans HJ, Hanemaaijer R, Mulder-Stapel AA, Prins FA, Dreef EJ, Kenter GG, Fleuren GJ and Gorter A. EMMPRIN-induced MMP-2 activation cascade in human cervical squamous cell carcinoma. *Int J Cancer* 2006; 118: 2991-2998.