

## Original Article

# Arrhythmogenic right ventricular dysplasia/ cardiomyopathy versus dilated right ventricular cardiomyopathy: a problematic autopsy diagnosis?

Peilin Zhang<sup>1,2</sup>, Anthony Dasaro<sup>3</sup>

<sup>1</sup>Kanawha Pathology Associates, Inc., Departments of <sup>2</sup>Pathology, <sup>3</sup>Medicine, St. Francis Hospital, Charleston, WV, USA

Received December 9, 2015; Accepted February 18, 2016; Epub March 1, 2016; Published March 15, 2016

**Abstract:** Arrhythmogenic right ventricular dysplasia-cardiomyopathy (ARVD-C) is a rare heart condition with characteristic thinning and fibroadipose tissue replacement of the myocardium of the right ventricular wall. We have seen 20 autopsy cases with morphologic features fitting the criteria of ARVD-C in our hospital in the past 5 years. The clinical characteristics of these patients were not those described in the literatures. Two of the 20 patients died suddenly without obvious cause, and only one of the 20 patients fit the classic clinical and morphologic description of the disease. The remaining patients were chronically ill with significant comorbidities, and the pre-mortem diagnosis of ARVD-C was not suspected in all these patients. We suspect that ARVD-C could be a spectrum of morphologic changes with variable clinical manifestations, and it may be far more common than that reported in the literature. The spectrum of the morphologic changes of the right ventricular wall raise questions of the diagnostic criteria at the time of autopsy and request for more clinical pathologic correlation. Alternatively, these morphologic features may represent a specific dilated right ventricular cardiomyopathy distinct from the classic description of arrhythmogenic right ventricular dysplasia/cardiomyopathy with genetic component.

**Keyword:** Right ventricular dysplasia, dilated cardiomyopathy, autopsy

## Introduction

Arrhythmogenic right ventricular dysplasia-cardiomyopathy (ARVD-C) is a rare and peculiar form of dilated cardiomyopathy first described in 1982 [1]. It primarily affects the right ventricular myocardium with fat and/or fibrous tissue replacement of the muscle [2, 3]. The clinical manifestation of the disease varies significantly, from total absence of clinical symptoms which is most common in the reported cases, to ventricular tachycardia, congestive heart failure, arrhythmia or sudden cardiac death [3]. Clinical recognition of this condition at the early stage is difficult due to the fact that clinical signs and symptoms of ARVD-C are non-specific, and the most commonly the diagnosis is made by pathologist during autopsy studies [1, 2, 4]. The disease is also recognized as a significant cause of sudden death in the young athletic population [1]. Histomorphologically, there have been two separate classes of ARVD-C, fatty infiltrate of right ventricular

wall, and fibrofatty infiltrate of the right ventricular wall [2, 4]. The relationship of the myofibers and the fibrofatty changes has been divided as infiltrative and cardiomyopathic patterns, and these patterns seem to correlate with distinct pathological processes, namely the infiltrative patterns are more commonly seen in patients with sudden death, and the cardiomyopathic patterns are seen more commonly in heart transplant patients with heart failure [2, 4]. There are proposed clinical diagnostic criteria including features of clinical, sonographic, MRI imaging and endomyocardial biopsy [5, 6]. Recent advances of molecular genetic studies revealed a host of gene mutations/variations encoding the desmosomal proteins, and the molecular classification of ARVD-C has been proposed [7, 8]. It is believed that ARVD-C is inherited in autosomal dominant fashion but there is large variability of penetrance [3, 8, 9]. Moreover, due to the limits of the genetic testing availability and the cost effectiveness of the genetic tests, the genetic classification of the

## Right ventricular cardiomyopathy at autopsy

**Table 1.** Patients' clinical characteristics and pathological changes

Age	Sex	Diagnosis	Co-morbidities	RV (mm)	Heart (grams)
62	M	ARVD-C	Sudden death, myocarditis	1.10	450
70	M	ARVD-C	Lymphoma, chemotherapy, Corpulmonale	0.25	585
70	M	ARVD-C	Asbestos exposure, simple CWP	0.40	612
67	F	ARVD-C	Sudden death, multiple morbidities	0.36	410
62	M	ARVD-C	Bypass, pacemaker, old infarcts, simple CWP	0.57	949
66	M	ARVD-C	Mild coronary atherosclerosis, simple CWP	0.37	480
66	M	ARVD-C	Moderate atherosclerosis, PMF	0.40	335
73	M	ARVD-C	Mild coronary atherosclerosis, PMF	0.39	480
61	M	ARVD-C	Old infarct, pacemaker, hypertrophic cardiomyopathy	0.68	850
60	M	ARVD-C	Moderate atherosclerosis, simple CWP	0.44	385
66	M	ARVD-C	Moderate atherosclerosis, simple CWP	0.35	530
57	M	ARVD-C	Old infarct, severe atherosclerosis, simple CWP	0.33	635
78	M	ARVD-C	Severe atherosclerosis, stent, PMF	0.42	495
60	M	ARVD-C	Hypertrophic cardiomyopathy, simple CWP	0.26	667
60	M	ARVD-C	PMF	0.51	390
35	M	ARVD-C	Hypertrophic cardiomyopathy	0.44	621
53	M	ARVD-C	Sudden death in hospital, pacemaker, severe acidosis	0.40	481
82	M	ARVD-C	Sudden death, infarct, bypass	0.73	720
69	M	ARVD-C	Hospice, bypass twice, asbestosis	0.37	640
60	M	ARVD-C	Old infarct, bypass, ICD, simple CWP	0.64	650

ARVD-C: arrhythmogenic right ventricular dysplasia-cardiomyopathy, CWP: coal worker's pneumoconiosis, PMF: progressive massive fibrosis. ICD: implantable cardioverter defibrillator.

disease is largely of academic interest in the past [10-12]. Practically there is no effective mean for definitive clinical diagnosis.

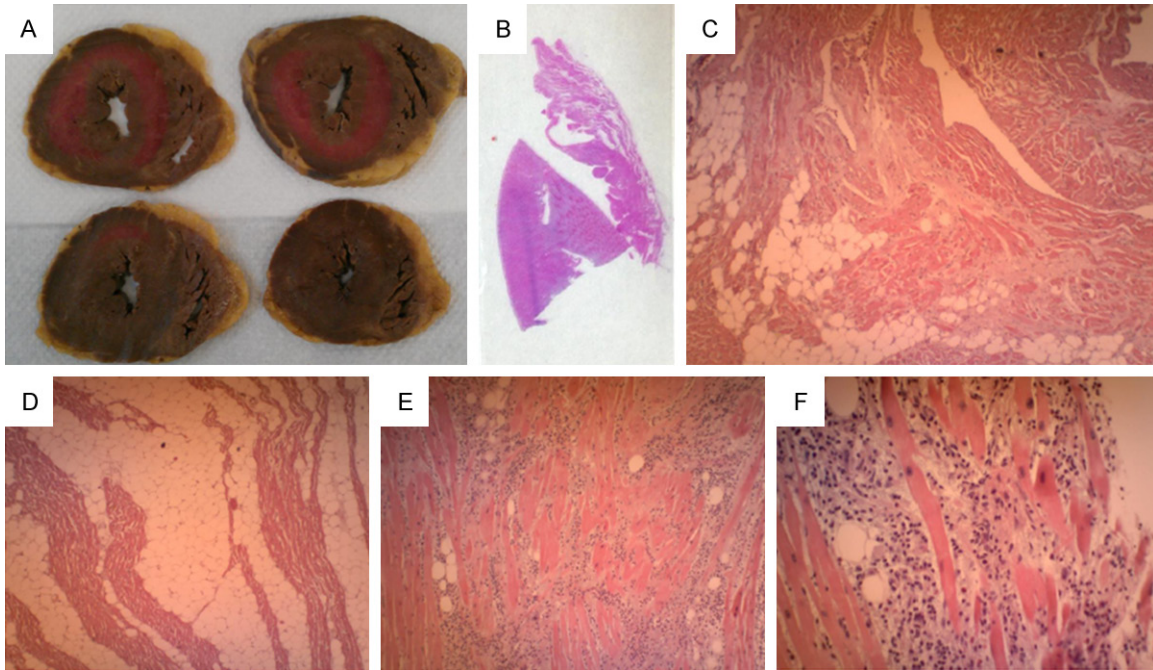
We have seen a number of cases in our small community hospital, and these cases are from our autopsy services in the past five years. Our hospital is a typical community acute care facility with no particular emphasis in heart care, and we have a handful autopsy cases annually primarily for occupational diseases such as coal worker's pneumoconiosis and asbestosis given the patient population we serve in the Appalachian regions with coal mining industry. Our cases do not fit the classic description of the disease in regard to demographics, clinical manifestations and our patients had significant comorbidities. Only one of the cases was sudden death without apparent causes, and the histologic features fit with the classic description of the disease [1]. The remaining cases were chronically ill patients with significant other comorbidities. None of the patients have significant family history of heart disease to our knowledge. We critically reviewed the literature and questioned our diagnosis and findings. Our patient demographics suggest that the prevalence of ARVD-C is much higher than that re-

ported, and the disease is more common than that realized. We also felt that the procedure at autopsy and the recognition of the disease may relate to the high prevalence in our hospital. There may have been significant right ventricular dysfunction in those chronically ill patients, but the clinical right ventricular dysfunction has not been attributed to the changes seen in the right ventricular wall. We present the features of these cases and discuss the clinical implication of our findings in respect to morphologic autopsy diagnosis and potential clinical right ventricular function. We also feel that the presence of these morphologic features in the right ventricular wall demands further investigation of the etiology, i.e., whether it is acquired due to other clinical comorbidities, such as inflammation, myocardial damage by drugs, or ischemic events or genetic changes.

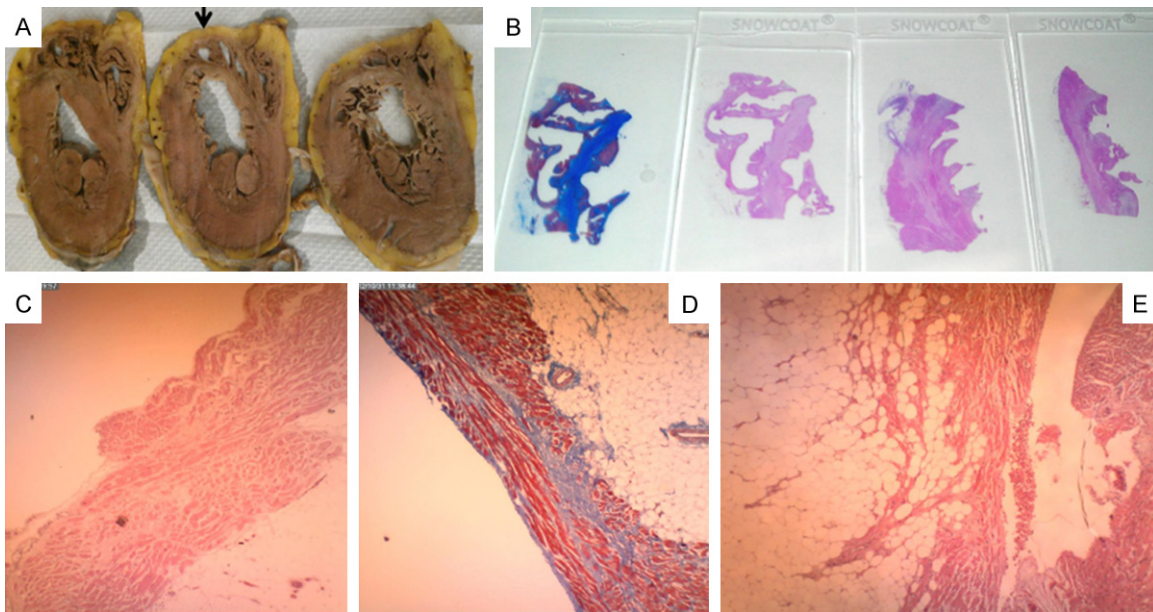
### Cases presentation

All of our autopsy cases were referred to us through local community for various reasons. Two patients were admitted to the hospital and died in the hospital. The characteristics of the patients and significant comorbidities were shown in **Table 1**. Conventional autopsy proce-

## Right ventricular cardiomyopathy at autopsy



**Figure 1.** Gross and microscopic photographs of the Case #1. A: Cross (horizontal) sections of the heart with biventricular views. B: Gross slide view of sections of right ventricular wall and kidney. C-F: Microscopic photos of the right ventricular wall with inflammatory cells at the apex (20×). Section F was taken at 200× magnification.



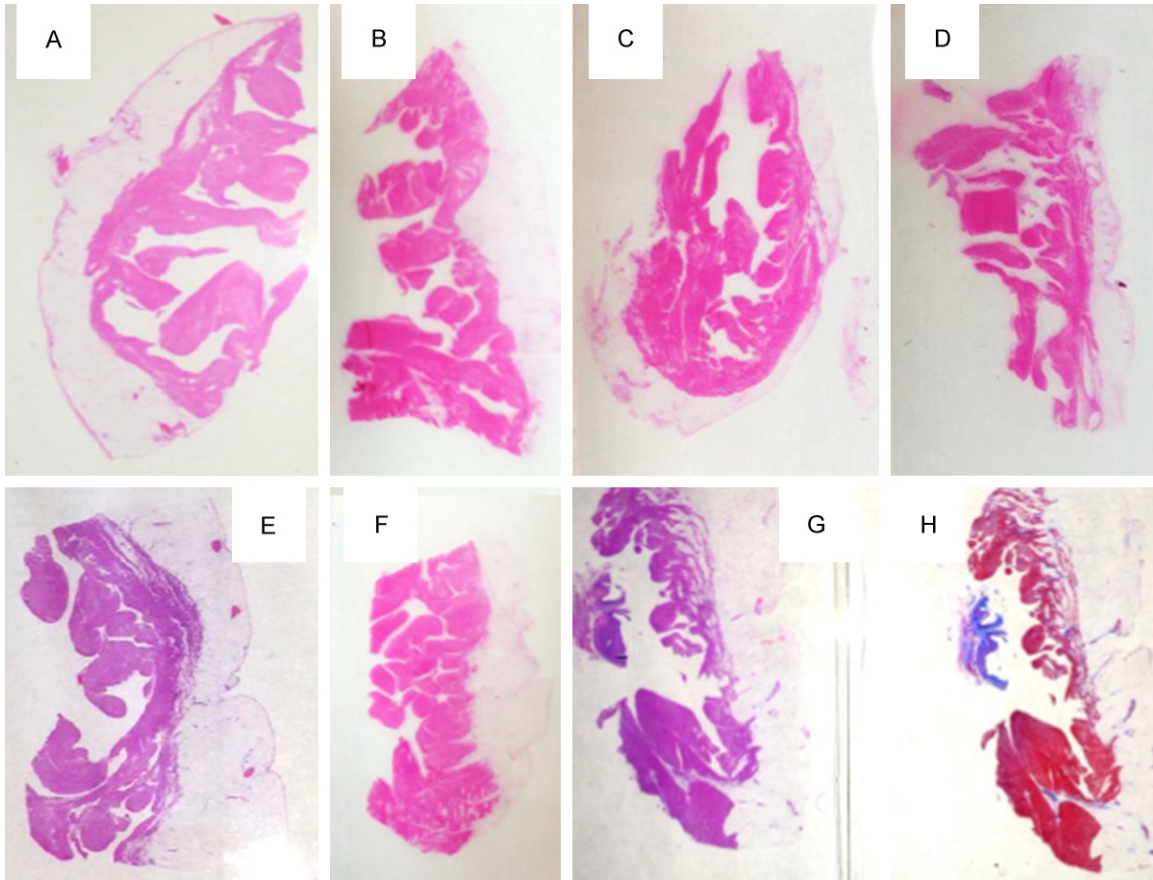
**Figure 2.** Gross and microscopic photographs of the case #2 in similar fashion to the case #1. A: Gross examination of cross section of the heart; One of the slides in B and D showed the Masson Trichrome stains of the right ventricular wall. Blue color highlights the collagen fibers within the myocardium. Sections C and E show microscopic photographs of the right ventricular wall. C was at 20× magnification and Sections E was taken at 100× magnification.

dures are performed, and the majority of the cases were submitted for the chest only examination. The heart examination is through coronal sectioning (cross or horizontal) from the

apex toward the valvular region first before examination of the valves and the coronary arteries. Both ventricular chambers can be visualized by the coronal (horizontal) sections



## Right ventricular cardiomyopathy at autopsy



**Figure 3.** Gross photographs of the whole microscopic slides containing the sections of the right ventricular walls from seven separate cases (A-G). (G, H) Represent the same section in Hematoxylin & Eosin stain and Masson trichrome stain.

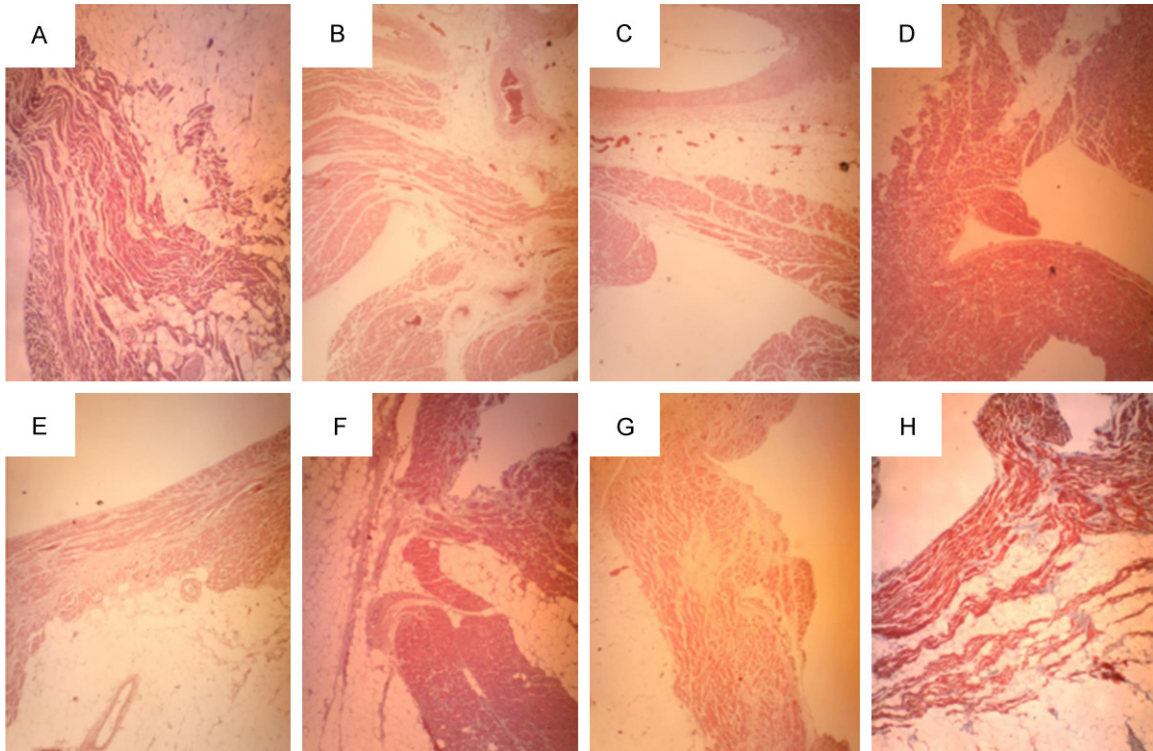
(**Figures 1** and **2**). All microscopic sections and measurements of the right ventricular walls were from the free lateral wall. The right ventricular sections were taken from the area 1-2 cm from the apex, and the measurement of the thickness of the right ventricular wall was performed on the microscopic slides using micrometry (Nikon Eclipse 50i). The thickness of the right ventricular myocardium is measured from the endocardium defined by the endothelial cell layer to the narrowest myocardium with fibrous/fibroadipose tissue. The right ventricular walls of all cases were grossly abnormal (thin) with fibrous fatty replacement of the myocardium. Heart weight in all patients were increased (cardiomegaly), and three of the 20 patients also showed hypertrophic cardiomyopathy with co-existing features of ARVD-C. None of the cases showed complete fibroadipose replacement of the entire myocardium, and none of the cases showed the right ventricular aneurysm or mural thrombosis. The examples of the histological micrographs of the right ventricular walls of the

seven selected cases are shown in **Figures 3** and **4**. Brief case summaries of the two selected cases of sudden death are listed below.

### Case #1

The case #1 was a 61 year old healthy white male with no significant medical history. He was a professional with regular medical check-up and the only medical history was seasonal allergy and annual flu shot. He collapsed on the floor while playing tennis on the court at a social gathering. He was intensively resuscitated on site and transferred to the hospital emergency room. The patient never regained the pulse, and the resuscitation was terminated. Autopsy was requested by the family to determine the cause of death. There was no significant coronary artery blockage, plaque build-up or narrowing. No significant gross or microscopic pathological findings were seen throughout the body except for a thin right ventricular wall with fibrous adipose tissue replacement in the myo-

## Right ventricular cardiomyopathy at autopsy



**Figure 4.** Microscopic photographs of the same sections in **Figure 3** representing 7 separate cases (A-G). Section (H) is a representative trichrome stain of the section (G) at 100× magnification.

cardium (**Figure 1**). Extensive search of ischemic changes within the myocardium and the cardiac conduction system including the S-A node and A-V node didn't reveal any remarkable abnormality. There were lymphocytic infiltrate within myocardium close to the apex with occasional eosinophils. Searching for viral myocarditis revealed no identifiable viruses by molecular studies at CDC (data not available). **Figure 1** shows the gross and microscopic photos with fibroadipose tissue replacement of the right ventricular wall, and the fibrous tissue is highlighted by the trichrome stain. This is the only case of sudden death without any clinical underlying identifiable causes or other comorbidities. However, the presence of lymphocytic myocarditis raises the questions of inflammation as a potential cause of the disease.

### Case #2

The case #2 was a 67 year old female with numerous medical conditions including renal cell carcinoma of the right kidney with adrenal involvement status post total right nephrectomy and right adrenalectomy, hyperthyroidism status post total thyroidectomy, total hysterectomy and bilateral salpingo-oophorectomy, and

multiple abdominal surgeries for lysis of adhesions. She died at home suddenly but peacefully at the night, and the family requested an autopsy study to determine the cause of death. Autopsy revealed a very thin right ventricular wall (0.36 mm) with scattered fibrous adipose tissue within the myocardium of the right ventricle (**Figure 2**).

### All other remaining cases

Two other cases were from the hospital in-patient service, and one of them showed hypertrophic cardiomyopathy as well as the features of ARVD-C. This patient's medical history was scarce, and there were flu-like symptoms for a week prior to the hospital admission. His medical condition didn't improve and he died of multi-organ failure in the hospital. The second case of the hospital in-patient service was a male with significant history of alcohol and the drug abuse. The patient had a pacemaker installed recently prior to his demise. Autopsy showed the presence of features of ARVD-C. All the remaining cases were from autopsies performed for other reasons. Seven representative sections of the right ventricular wall from the seven patients are shown in **Figures 3** and **4**.

## Right ventricular cardiomyopathy at autopsy

Each section represents one patient's specimen except for section H which is the trichrome stain of the specimen G in both **Figures 3** and **4**. The sections were all taken from the free lateral wall of the right ventricle as describe above.

As shown in the **Table 1**, there is no particular trend in the heart weight and the measurement of the right ventricular myocardium. The patients were older than those described previously with other co-existing medical conditions [1, 2, 4].

### Discussion

ARVD-C has been reported as a rare disease involving primarily the right ventricular wall with variable degrees of involvement of the left ventricle [1, 2, 4]. It is considered a variant of dilated cardiomyopathy with genetic components and variable penetrance [13]. It is commonly associated with sudden death of young athletic population. Our cases revealed a different spectrum of the disease and we have a number of questions related to pathological findings and the clinical manifestations. First, is our histological assessment correct and diagnostic of ARVD/C? Strictly speaking, histopathological diagnosis is objective, and based on the morphological changes, we felt our cases fit the diagnostic criteria of the disease on both gross and microscopic examinations. The thickness of the right ventricle in our cases ranges from 0.1 to 1.1 mm (see above figures and **Table 1**), and all the cases showed variable degrees of fibrous adipose infiltrate within the myocardium (illustrated by trichrome stain). Our measurement results of the thickness of the right ventricular myocardium are more profound than those reported [4], and this discrepancy could be the results of our sectioning and sampling methods from those reported [4]. We only sectioned and submitted the thinnest part of the right ventricular wall at the 1-2 cm area from the apex for microscopic examination, and we measured the thickness of the myocardium on the microscopic slides using micrometry excluding the fibrous fatty tissue instead of gross measurement of the myocardium. Furthermore, we did not measure other parts of the right ventricular wall for comparison. The presence of mature adipose tissue only has been proposed to be a separate disease entity from the classical ARVD-C [2, 4].

Second, none of our cases showed any clinical evidence of arrhythmia, the cardinal sign of the disease. Sudden cardiac death is a terminal event of arrhythmia without evidence of heart failure. Based on the original description of the disease and the study population, it is clear that sudden death of young athletics is due to arrhythmia [1]. Our patient population is very different from those of the original study cases, and none of our patients had clinical suspicion of the diagnosis of ARVD-C. Most of our patients were chronically ill with other significant medical conditions, and the progression of the disease is likely due to dysfunction of the right ventricle.

Third, given the fact that genetically mutant mice models recapitulate almost all the clinical and pathological features of the disease [14], it is reasonable to believe the disease is of genetic bases, or alternatively, the genetic changes play a contributing role in the pathogenesis. Based on the morphologic features of our patients from a community hospital, we felt the prevalence is much higher than we have previously thought. It is our suspicion that the right ventricular dysfunction, other than arrhythmia, is more clinically relevant and the right ventricular dysfunction in clinical setting is far more common.

Finally, there is a strong genetic bases to ARVD-C based on the published reports [15-17], and the autopsy diagnosis of ARVD-C is a significant burden to the family members, given the severity and potential effects of the disease on the children and offspring. It is important to be accurate in autopsy diagnosis. However, more definitive diagnostic criteria are difficult to be established given the wide variation of the sectioning methods, the broader spectrum of morphologic changes of the heart, and perception of the disease (rare genetic disease causing arrhythmia). The diagnostic term of "dilated right ventricular cardiomyopathy" is probably more acceptable for the patient's family and the medical community than the specific diagnosis of ARVD-C. However, the meaning and the clinical significance of "dilated right ventricular cardiomyopathy" are difficult to define based on the morphologic assessment alone. Furthermore, the right ventricular dysfunction will probably not improve with only medical treatment, since the right ventricular myocardium becomes thin with fibrous fatty



## Right ventricular cardiomyopathy at autopsy

replacement (organic changes). Certain patients in clinical setting will probably benefit with implantable cardioverter defibrillator (ICD) or synchronous pacemaker.

Two of the 20 cases had histologic evidence of myocardial damage (the case #1 showed chronic myocarditis with lymphocytic infiltrate, and one other case had history of chemotherapy for lymphoma with a potential of myocardial damage, although no detailed chemotherapy regimen is known). Myocardial damage with fibroblastic proliferation and repair changes is an appealing hypothesis in pathogenesis of the disease.

Recent advancement of molecular genetics of ARVD-C shed the light on the pathogenesis of certain desmosomal gene mutations with variable expressions. Next generation DNA sequencing with high throughput targeting desmosomal genes and other pathways such as inflammatory, wound healing, fibroblastic signaling and adipogenesis or others will certainly help define more genetic changes in the patient population.

### Disclosure of conflict of interest

None.

**Address correspondence to:** Dr. Peilin Zhang, Department of Pathology, St. Francis Hospital, 333 Laidley Street, Charleston, WV25301. E-mail: PZMLLC@gmail.com

### References

- [1] Marcus FI, Fontaine GH, Guiraudon G, Frank R, Laurenceau JL, Malergue C and Grosgeat Y. Right ventricular dysplasia: a report of 24 adult cases. *Circulation* 1982; 65: 384-398.
- [2] d'Amati G, Leone O, di Gioia CR, Magelli C, Arpesella G, Grillo P, Marino B, Fiore F and Gallo P. Arrhythmogenic right ventricular cardiomyopathy: clinicopathologic correlation based on a revised definition of pathologic patterns. *Hum Pathol* 2001; 32: 1078-1086.
- [3] Watkins H, Ashrafian H and Redwood C. Inherited cardiomyopathies. *N Engl J Med* 2011; 364: 1643-1656.
- [4] Burke AP, Farb A, Tashko G and Virmani R. Arrhythmogenic right ventricular cardiomyopathy and fatty replacement of the right ventricular myocardium: are they different diseases? *Circulation* 1998; 97: 1571-1580.
- [5] Marcus FI, McKenna WJ, Sherrill D, Basso C, Bauce B, Bluemke DA, Calkins H, Corrado D, Cox MG, Daubert JP, Fontaine G, Gear K, Hauer R, Nava A, Picard MH, Protonotarios N, Saffitz JE, Sanborn DM, Steinberg JS, Tandri H, Thiene G, Towbin JA, Tsatsopoulou A, Wichter T and Zareba W. Diagnosis of arrhythmogenic right ventricular cardiomyopathy/dysplasia: proposed modification of the task force criteria. *Circulation* 2010; 121: 1533-1541.
- [6] Marcus F, Basso C, Gear K and Sorrell VL. Pitfalls in the diagnosis of arrhythmogenic right ventricular cardiomyopathy/dysplasia. *Am J Cardiol* 2011; 105: 1036-1039.
- [7] Asimaki A, Tandri H, Huang H, Halushka MK, Gautam S, Basso C, Thiene G, Tsatsopoulou A, Protonotarios N, McKenna WJ, Calkins H and Saffitz JE. A new diagnostic test for arrhythmogenic right ventricular cardiomyopathy. *N Engl J Med* 2009; 360: 1075-1084.
- [8] Cox MG, van der Zwaag PA, van der Werf C, van der Smagt JJ, Noorman M, Bhuiyan ZA, Wiesfeld AC, Volders PG, van Langen IM, Atsma DE, Dooijes D, van den Wijngaard A, Houweling AC, Jongbloed JD, Jordaens L, Cramer MJ, Doevendans PA, de Bakker JM, Wilde AA, van Tintelen JP and Hauer RN. Arrhythmogenic right ventricular dysplasia/cardiomyopathy: pathogenic desmosome mutations in index-patients predict outcome of family screening: Dutch arrhythmogenic right ventricular dysplasia/cardiomyopathy genotype-phenotype follow-up study. *Circulation* 2011; 123: 2690-2700.
- [9] Lakdawala NK, Winterfield JR and Funke BH. Dilated cardiomyopathy. *Circ Arrhythm Electrophysiol* 2012; 6: 228-237.
- [10] Lakdawala NK, Funke BH, Baxter S, Cirino AL, Roberts AE, Judge DP, Johnson N, Mendelsohn NJ, Morel C, Care M, Chung WK, Jones C, Psychogios A, Duffy E, Rehm HL, White E, Seidman JG, Seidman CE and Ho CY. Genetic testing for dilated cardiomyopathy in clinical practice. *J Card Fail* 2012; 18: 296-303.
- [11] van der Smagt JJ, van der Zwaag PA, van Tintelen JP, Cox MG, Wilde AA, van Langen IM, Ummels A, Hennekam FA, Dooijes D, Gerbens F, Bikker H, Hauer RN and Doevendans PA. Clinical and genetic characterization of patients with arrhythmogenic right ventricular dysplasia/cardiomyopathy caused by a plakophilin-2 splice mutation. *Cardiology* 2012; 123: 181-189.
- [12] Teekakirikul P, Kelly MA, Rehm HL, Lakdawala NK and Funke BH. Inherited cardiomyopathies: molecular genetics and clinical genetic testing in the postgenomic era. *J Mol Diagn* 2012; 15: 158-170.
- [13] van der Zwaag PA, Jongbloed JD, van den Berg MP, van der Smagt JJ, Jongbloed R, Bikker H,

## Right ventricular cardiomyopathy at autopsy

- Hofstra RM and van Tintelen JP. A genetic variants database for arrhythmogenic right ventricular dysplasia/cardiomyopathy. *Hum Mutat* 2009; 30: 1278-1283.
- [14] Pilichou K, Bezzina CR, Thiene G and Basso C. Arrhythmogenic cardiomyopathy: transgenic animal models provide novel insights into disease pathobiology. *Circ Cardiovasc Genet* 2011; 4: 318-326.
- [15] Lazzarini E, Jongbloed JD, Pilichou K, Thiene G, Basso C, Bikker H, Charbon B, Swertz M, van Tintelen JP and van der Zwaag PA. The ARVD/C genetic variants database: 2014 update. *Hum Mutat* 2015; 36: 403-410.
- [16] van der Zwaag PA, Jongbloed JD and van Tintelen JP. Genetic diagnosis through whole-exome sequencing. *N Engl J Med* 2014; 370: 1067.
- [17] Romero J, Mejia-Lopez E, Manrique C and Lucariello R. Arrhythmogenic Right Ventricular Cardiomyopathy (ARVC/D): A Systematic Literature Review. *Clin Med Insights Cardiol* 2013; 7: 97-114.